

# Pediatric Graves' Disease: A Case Report

BY - DR. SUNEETHA (ASSOCIATE PROFESSOR)  
DR. VANI BAI ( DESSAIGNATED PROFESSOR)  
Dr. USHA RANI ( POST GRADUATE)

Pediatric Department old ggh, vijayawada

## ABSTRACT

Graves' disease (GD) is the most common cause of hyperthyroidism in children. Antithyroid drugs (ATD) are recommended as the initial treatment, but the major concern is the high relapse rate (30%) as remission is achieved after a first course of ATD. Alternative treatments, such as radioactive iodine or thyroidectomy, are considered in cases of relapse, lack of compliance, or ATD toxicity. Here we present a case report of 11 years old Andhrapradesh girl who presented with neck swelling tremor, nervousness, protrusion of both eyes and sleep disturbances. She diagnosed as Graves' disease and started on carbimazole treatment.

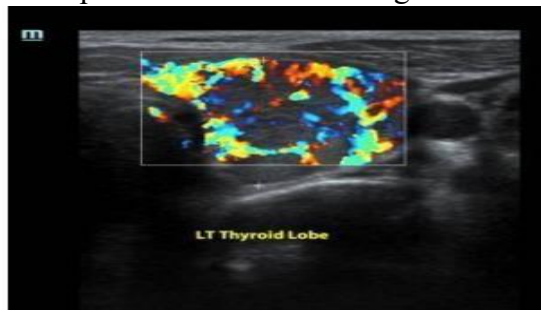
**Key words:** Hyperthyroidism, Graves disease, Thyroid, Methimazole, Propylthiouracil, Radioactive iodine.



Figure 1: Bilateral exophthalmos

## INTRODUCTION

Hyperthyroidism is a rare but serious disease in childhood. (1) The most common cause is Graves' disease (GD), an autoimmune disorder resulting from thyrotropin (TSH) receptor stimulation by autoantibodies. Other causes include Acute or subacute thyroiditis, chronic lymphocytic thyroiditis, administration of thyroid hormones and/or iodides, McCune-Albright syndrome, TSH-secreting pituitary tumors and Thyroid hormone resistance. (2) Here we present classical case of graves' disease in



young girl with literature review.

## CASE REPORT

A 11 years old girl presented to pediatric endocrine outpatient clinic with history of difficulty in swallowing, intermittent in nature. There is of nervousness, increase in the appetite, No H/O sleep disturbance, palpitation, diarrhea, sweating and tremor.

The mother noticed swelling in the middle of child neck. It was started gradually not associated with pain or difficult in swallowing. No history of muscle pain, weakness, hair loss, shortness of breath, skin rash or depression. Patient was not on medication. There is no past medical and surgical history. Vaccination was up to date.

Developmental parameters were appropriate for age. She was on family diet with average International Journal of Health Sciences & Research (www.ijhsr.org)

*Dr.Badi Alenazi et al. Pediatric Graves' Disease: A Case Report*

International Journal of Health Sciences & Research (www.ijhsr.org)

331

Vol.7; Issue: 12; December 2017 appetite. No consanguinity between parents. She has 1 other sibling live and healthy. There is no family history of thyroid disorder. On examination, he was not dysmorphic, weight, height were at 50<sup>th</sup>, 50<sup>rd</sup> percentile respectively. The patient had a heart rate of 102 beats per minute. Blood pressure of 142/62 mm Hg. Hand examination revealed fine tremor and sweating, Eye examination revealed exophthalmos. (Figure1). There is diffuse non tender midline swelling move with swallowing and not move with protruding tongue, not extent to upper chest. No bruit on auscultation. Examination of chest showed equal air entry with no added sound. Cardiac examination was unremarkable. There was no hepatosplenomegaly, no skin changes. Child had normal muscle tone and power.

Child can walk. Musculoskeletal examination was unremarkable, Tanner stage examination showed prepubertal stage. Investigations showed Hemoglobin 13 g dl, white blood cell (WBC)  $9 \times 10^3 / L$ . Serum urea and electrolytes were normal. Liver function tests were normal, renal profile was normal. Hormonal analysis revealed Ft3: 48.95 mcg/ml

Ft4 : < 100 mcg/ml

TSH : >0.008 mIU/ml

Thyroid-stimulating Ig of 166 % (normal,  $\leq 125$ )

Anti tpo -137. 6 IU/ml

Ultrasound of neck showed both thyroid lobes and isthmus are enlarged. Right lobe  $19.5 \times 21 \times 35$  mm is bulkier than left  $15 \times 15 \times 38$  mm with heterogeneous echo pattern and very high vascularity on color Doppler. S/O thyroiditis. Few submental lymph nodes are enlarged. (figure3) Radioactive iodine (or technetium99) uptake not available in our center. *Figure 1: Bilateral exophthalmos Figure 3: US neck revealed very high vascularity on color Doppler on left thyroid lobe.*

## DISCUSSION

GD is more frequent in female than in male patient in both adult and children. It can occur at any age during childhood, but it increases in frequency with age, peaking during adolescence. The incidence is about 0.1 per 100 000 person-years in young children to 3 per 100 000 person per years in adolescents. (1) The cause of GD remains unclear, but it is believed to result from a complex interaction between genetic factors, environmental factors and the immune system. The immune system produces an antibody [TSH receptor antibody (TRAb)] that stimulates the thyroid gland to produce *Dr.Badi Alenazi et al. Pediatric Graves' Disease: A Case Report*

International Journal of Health Sciences & Research (www.ijhsr.org)

332 Vol.7; Issue: 12; excess thyroid hormone. Genetic susceptibility to the disease is thought to be polygenic. (2) The thyroid-stimulating immunoglobulin (TSI) binds to and stimulates the TSH receptor on the thyroid cell membrane resulting in follicular cell growth, vascularity increase, and in excessive synthesis and secretion of thyroid

hormone. The thyroid gland typically displays lymphocytic infiltration, with T lymphocyte abnormality and absence of follicular destruction. T cells activate local inflammation and tissue remodelling by producing and releasing cytokines, leading to B-cell dysregulation and increase in autoantibody production. An imbalance between pathogenic and regulatory T cells is thought to be involved in both the development of GD and its severity. (3) The symptoms of hyperthyroidism include excessive physical activity, flushing, palpitations, tremor, tachycardia weight loss, accelerated linear growth, reduced bone mineralization, and poor school performance. In pediatric GD, ophthalmopathy occurs in less than 50% of patients and is usually mild when present. (4) Hyperthyroidism is non self-limiting disease so, treatment is mandatory. Therapeutic approaches for GD include the antithyroid drugs (ATDs) propylthiouracil (PTU) or methimazole (MMI), radioactive iodine (<sup>131</sup>I), or surgery. (5-6) ATD therapy is usually recommended as the initial treatment for hyperthyroidism in children and adolescents. The most commonly used ATDs are carbimazole and its active metabolite, methimazole (MMI) and propylthiouracil (PTU). These drugs inhibit thyroid hormone synthesis by interfering with the thyroid peroxidase-mediated iodination of tyrosine residues in thyroglobulin. PTU can also block the conversion of thyroxine (T<sub>4</sub>) to triiodothyronine (T<sub>3</sub>), whereas MMI cannot. Both MMI and PTU are associated with minor reactions (rash, urticaria, arthralgia, gastrointestinal problems) in about 5% to 25% of cases. The frequency of agranulocytosis is between 0.2 and 0.5% for both drugs, and other rare but serious side effects include drug-induced hepatitis. (2) PTU is not recommended anymore because of the high risk of PTU-induced hepatitis. (7) The initial starting dose of MMI (or carbimazole) is 0.5 to 1 mg/kg/day, with a maximum dose of 30mg per day. After two to four weeks, when thyroid hormone secretion is effectively blocked and thyroid hormone levels have normalised, the initial dose is gradually reduced by 30 to 50%. (8) Less than 30% of children achieve lasting remission after about 24 months of ATD. (9- 11) Near-total thyroidectomy and RAI therapy are the definitive therapeutic options, but both carry a high risk of permanent hypothyroidism. However, hypothyroidism is preferable to hyperthyroidism as it is easier to treat, and hyperthyroidism is associated with serious morbidities such as cardiovascular diseases and osteopenia. (1) Total (or near-total) thyroidectomy is often currently preferred to subtotal (or partial) thyroidectomy to reduce the risk of recurrent hyperthyroidism. (11) Levothyroxine replacement therapy should be initiated within days of surgery and the patient should be subject to long-term follow-up. Complications such as hypoparathyroidism, vocal cord palsy due to recurrent laryngeal nerve injury, and keloid formation are relatively rare when the operation is performed by a paediatric surgeon with extensive experience and are estimated at about 15%. For patients with recurrent hyperthyroidism after surgery, RAI treatment is recommended. (11) Surgery is often recommended only in patients with a large goiter or with ophthalmopathy. For other Cases, however, there is still some debate about whether RAI treatment or surgical ablation should be preferred as the definitive treatment for paediatric GD. (12)

*Dr. Badi Alenazi et al. Pediatric Graves' Disease: A Case Report*

International Journal of Health Sciences & Research ([www.ijhsr.org](http://www.ijhsr.org)) 333  
Vol.7; Issue: 12; December 2017 RAI treatment is effective in children with hyperthyroidism due to GD, and most patients can be successfully treated with a single oral dose. Low dose aims to cure hyperthyroidism without resulting in hypothyroidism, but the relapse rate is high. (13) Hypothyroidism is likely to occur after treatment, and appropriate doses of L-T<sub>4</sub> must therefore be administered

throughout the patient's life. If hyperthyroidism persists 3 to 6 months after therapy, retreatment with I 131 is indicated. However, RAI should be avoided in very young children because of an increased potential risk of neoplasia. Concerns about potential thyroid malignancy, hyperparathyroidism and high mortality rates have highlighted the need for a large, randomised control study with longterm follow-up to settle this issue definitively. (1315) Remission of GD is defined as being biochemically euthyroid or hypothyroid for one year or more after the discontinuation of ATDs. (9-10)

## CONCLUSION

In our patient who is 4 years old girl presented to endocrine OPD with complaints of neck swelling tremor, nervousness, protrusion of both eyes and sleep disturbances. There is strong family history of thyroid diseases. On examination, she had goiter, exophthalmos and fine tremor. On investigation, patient had hyperthyroidism and positive thyroid stimulating Immunoglobulin. On the basis of these findings, he was diagnosed as graves' disease, and was started on carbimazole and propranolol. Clinician should keep in mind that Graves' disease is the most common cause of hyperthyroidism in children.

## REFERENCES

1. Lavard L, Ranlov I, Perrild H, Andersen O, Jacobsen BB. Incidence of juvenile thyrotoxicosis in Denmark, 1982-1988. A nationwide study. *Eur J Endocrinol* 1994; 130:565-568.
2. Juliane Léger, Jean Claude Carel. Hyperthyroidism in Childhood: Causes, When and How to Treat. *J Clin Res Pediatr Endocrinol*. 2013 Mar; 5(Suppl 1): 50-56.
3. Saitoh O, Nagayama Y. Regulation of Graves' hyperthyroidism with naturally occurring CD4+CD25+ regulatory T cells in a mouse model. *Endocrinology* 2006; 147: 2417-2422. 2006 Jan 26.,
4. Rivkees SA, Sklar C, Freemark M: Clinical review 99: The management of Graves' disease in children, with special emphasis on radioiodine treatment. *J Clin Endocrinol Metab* 1998, 83:3767-3776.
5. Weetman AP: Grave's disease 1835-2002. *Horm Res* 2003, 59(Suppl 1):114-118.
6. Chapman EM: History of the discovery and early use of radioactive iodine. *JAMA* 1983, 250:2042-2044.
7. Rivkees SA, Mattison DR. Ending propylthiouracil-induced liver failure in children. *N Engl J Med* 2009;360:1574-1575.
8. Cooper DS. Antithyroid drugs. *N Engl J Med* 2005;352:905-917.
9. Glaser NS, Styne DM. Predictors of early remission of hyperthyroidism in children. *J Clin Endocrinol Metab* 1997;82:1719-1726.
10. Hamburger JI. Management of hyperthyroidism in children and adolescents. *J Clin Endocrinol Metab* 1985;60:1019-1024.
11. Zimmerman D, Gan-Gaisano M. Hyperthyroidism in children and adolescents. *Pediatr Clin North Am* 1990; 37: 1273-1295.
12. Lee JA, Grumbach MM, Clark OH. The optimal treatment for pediatric Graves' disease is surgery. *J Clin Endocrinol Metab* 2007;92:801-803.
13. Rivkees SA, Cornelius EA. Influence of iodine-131 dose on the outcome of hyperthyroid children. *Pediatrics* 2003; 111:745-749.
14. Read CH Jr, Tansey MJ, Menda Y. A 36 year retrospective analysis of the efficacy and safety of radioactive iodine in treating young Graves' patients. *J Clin Endocrinol Metab* 2004;89:4229-4233.
15. Metso S, Jaatinen P, Huhtala H, Auvinen A, Oksala H, Salmi J. Increased cardiovascular and cancer mortality after radioiodine treatment for hyperthyroidism. *J Clin Endocrinol Metab*. 2007 Jun;92(6):2190-6.

*Dr. Badi Alenazi et al. Pediatric Graves' Disease: A Case Report*

How to cite this article: Alenazi B, Alenazi A, Alshaya A et al. Pediatric graves' disease: a case report. *Int J Health Sci Res*. 2017; 7(12):330-333.